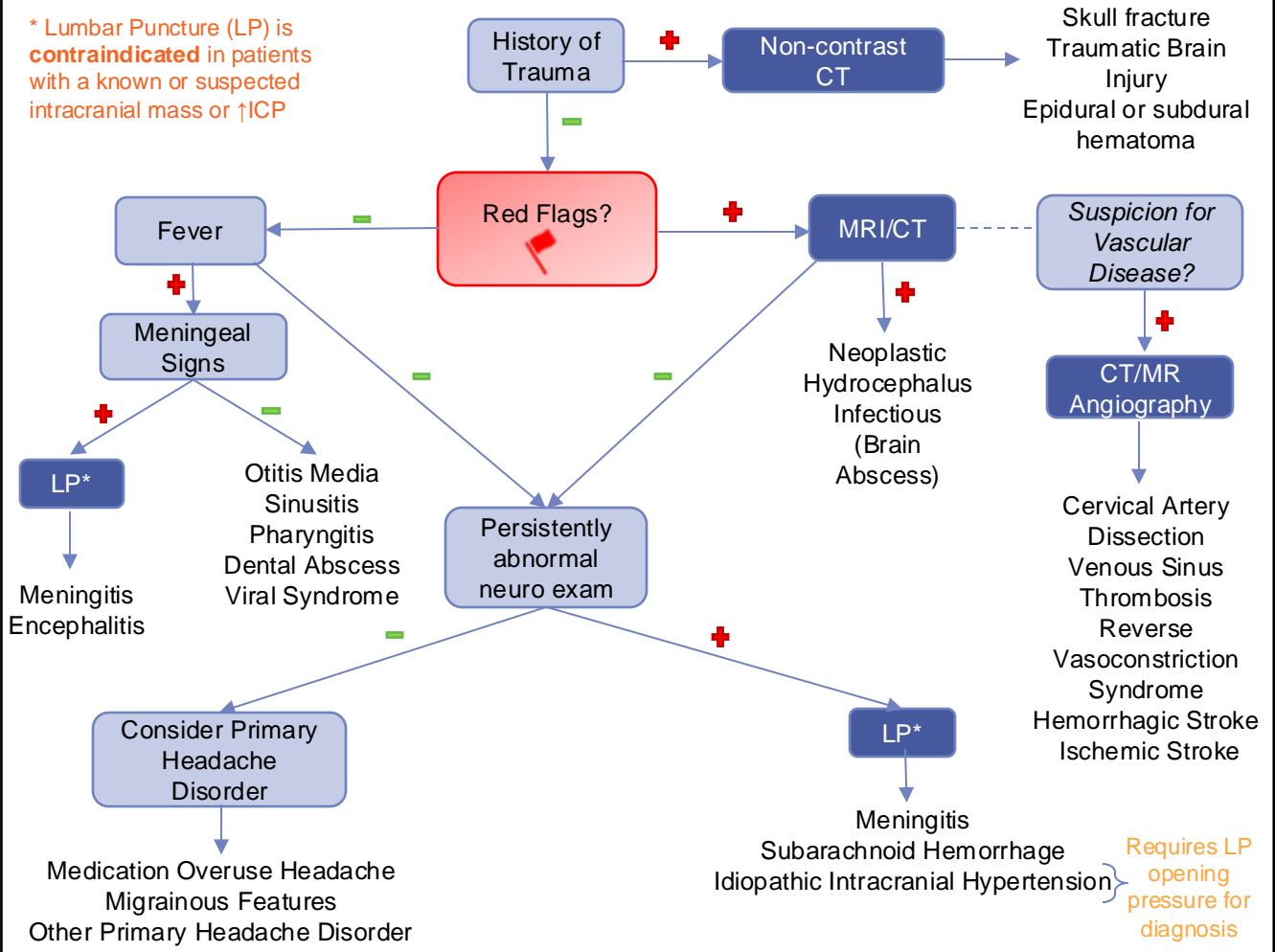




## ACUTE SEVERE HEADACHE

\* Lumbar Puncture (LP) is **contraindicated** in patients with a known or suspected intracranial mass or ↑ICP



### HISTORY

- Abrupt onset (“worst headache of my life”, thunderclap)
- Positional association
- Occurs soon after waking or awakens from sleep
- Precipitated by Valsalva
- Progressive and worsening over time
- Focal or global neurological deficits

### PHYSICAL EXAM

- Hypertension with brady- or tachycardia → suggestive of increased intracranial pressure (ICP)
- Prolonged altered mental status (>60 minutes)
- Papilledema
- Neck stiffness
- Visual Changes
- Ataxia
- Dysmetria
- Focal neurologic deficits (e.g. cranial nerve palsy, motor, somatosensory)

### INDICATIONS FOR NEUROIMAGING

**Red flag findings:** Focal neuro deficits, concern for ↑ICP, thunderclap onset

- Non-contrast CT – rapid assessment
- CT – often first-line if clinically stable
- Inpatient MRI
- Consider Angiography (CTA or MRA) if suspicious for vascular etiologies

**Chronic, progressive headache with normal neuro exam:**

- Expedited outpatient MRI

**Neurocutaneous findings:**

- Non-urgent MRI
- Genetic workup